




**2026** ACG'S ENDOSCOPY SCHOOL  
& ACG / LGS REGIONAL  
POSTGRADUATE COURSE

**MARCH 6-8, 2026** | HILTON NEW ORLEANS RIVERSIDE  
NEW ORLEANS, LOUISIANA

  Register online: [meetings.gi.org](https://meetings.gi.org)



The banner features a large orange '2026' on the left. The main title is in purple and blue. The dates and location are in blue. A circular inset on the right shows a cityscape of New Orleans. The background has a blue and purple curved graphic on the right side.

1



**2026** ACG'S HEPATOLOGY SCHOOL  
& ACG / FGS ANNUAL  
SPRING SYMPOSIUM

**MARCH 20-22, 2026** | HYATT REGENCY COCONUT POINT  
NAPLES, FLORIDA

  Register online: [meetings.gi.org](https://meetings.gi.org)

The banner features a large orange '2026' on the left. The main title is in maroon and blue. The dates and location are in maroon. A circular inset on the right shows a pier over the ocean at sunset. The background has a maroon and blue curved graphic on the right side.

2



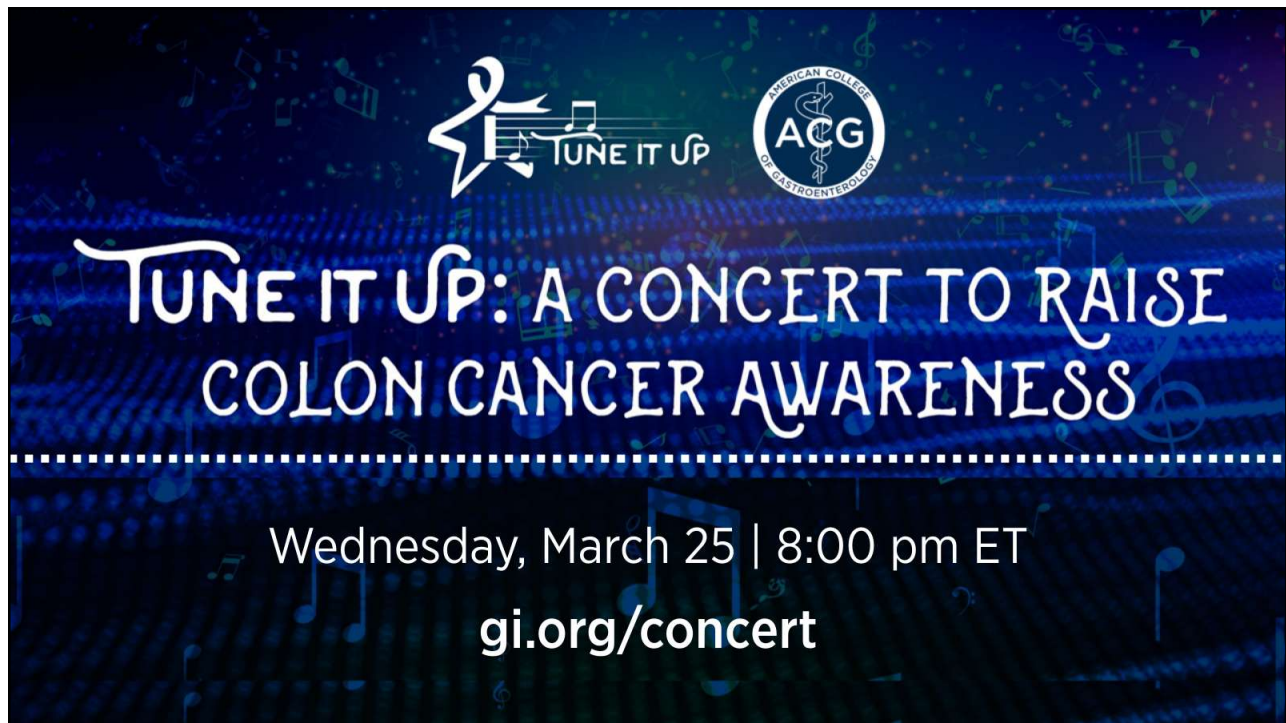
**2026** **ACG SUMMER SCHOOL SERIES:**  
WOMEN'S LEADERSHIP COURSE,  
IBD SCHOOL AND  
ESOPHAGUS SCHOOL



**JUNE 5-7, 2026** | WASHINGTON MARRIOTT AT METRO CENTER  
WASHINGTON, DC

 Register online: [meetings.gi.org](https://meetings.gi.org)



3



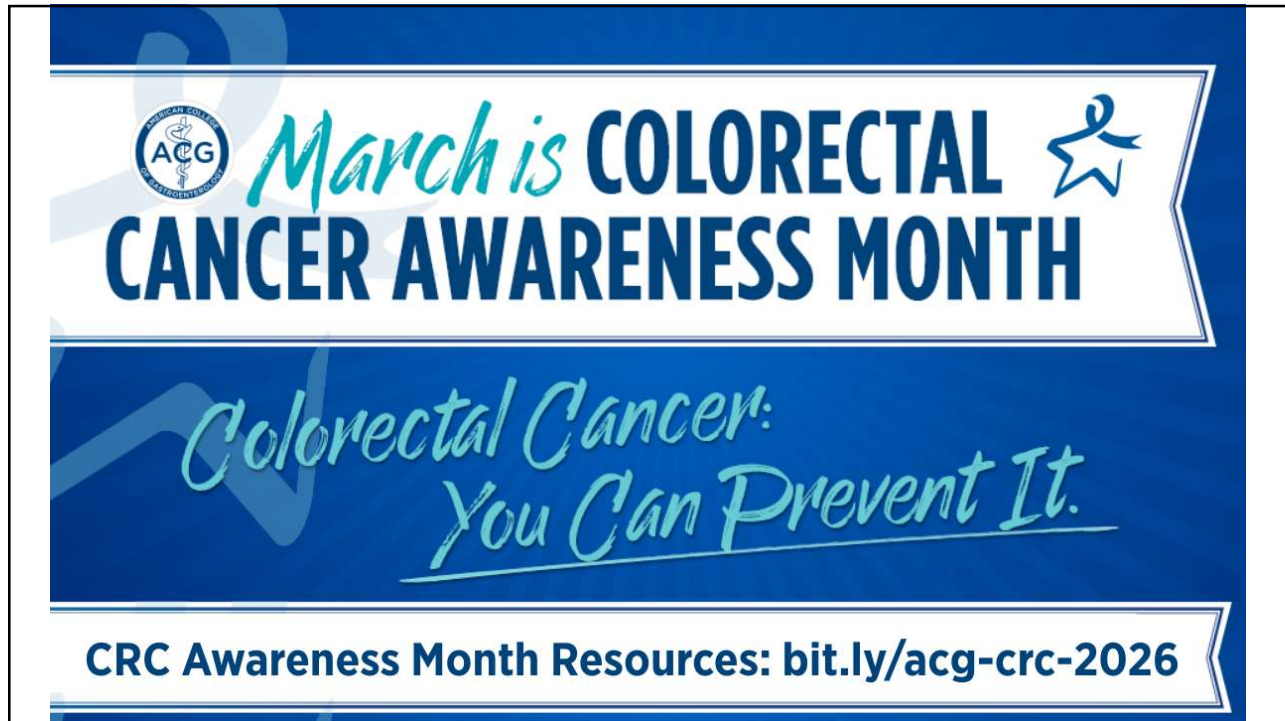
 


**TUNE IT UP: A CONCERT TO RAISE  
COLON CANCER AWARENESS**

Wednesday, March 25 | 8:00 pm ET

[gi.org/concert](https://gi.org/concert)

4



**ACG** *March is* **COLORECTAL**   
**CANCER AWARENESS MONTH**

*Colorectal Cancer:  
 You Can Prevent It.*

**CRC Awareness Month Resources: [bit.ly/acg-crc-2026](https://bit.ly/acg-crc-2026)**

5



**ACG 2026**  
 OCTOBER 9-14, 2026 | NASHVILLE, TN

**CALL FOR Abstracts**

**SUBMISSION SITE OPENS MARCH 2, 2026**

**SUBMISSION DATES:  
 MARCH 2 - JUNE 1, 2026**

The American College of Gastroenterology invites you to submit abstracts for presentation at the 2026 Annual Scientific Meeting and Postgraduate Course. Abstracts must be clinical or research-oriented, with a focus on gastroenterology or hepatology.

**IMPORTANT DATES**

- > **MARCH 2**  
 Submission Site OPENS
- > **JUNE 1 | 11:59 PM ET**  
 Submission Site CLOSES (No Exceptions!)
- > **BY JULY 17**  
 Notification of abstract ACCEPTANCE
- > **SEPTEMBER 16**  
 Presenting Authors MUST REGISTER as an attendee

**ABSTRACT CATEGORIES**


- Biliary/Pancreas
- Colon
- Colorectal Cancer Prevention
- Diet, Nutrition, and Obesity
- Endoscopy Video
- Esophagus
- Functional Bowel Disease
- General Endoscopy
- GI Bleeding
- IBD
- Infections and Microbiome
- Interventional Endoscopy
- Liver
- Pediatrics
- Practice Management
- Small Intestine
- Stomach and Spleen
- Clinical Vignettes/Case Reports

SCAN FOR THE SUBMISSION SITE  
 [bit.ly/ACG2026\\_Abstracts](https://bit.ly/ACG2026_Abstracts)

6

Virtual Grand Rounds universe.gi.org

## Participating in the Webinar




Moderator:  
Neha V. Patel, MD, FACP

All attendees will be muted and will remain in "Listen Only Mode"

Type your questions here so that the moderator can see them.  
Not all questions will be answered but we will get to as many as possible.

A handout with the slides and room to take notes can be downloaded from your control panel.



7

Virtual Grand Rounds universe.gi.org

## ACG Virtual Grand Rounds

### Join us for upcoming Virtual Grand Rounds!





Week 11 – Thursday, March 12, 2026  
 Update on Best Practices for Colonoscopy Bowel Preparation  
 Faculty: Carol A. Burke, MD, MACG  
 Moderator: Ryan K. Fawley, MD, FACP  
**At Noon and 8pm Eastern**




Week 12 – Thursday, March 19, 2026  
 AI in Colonoscopy and Beyond  
 Faculty: Seth A. Gross, MD, FACP  
 Moderator: Pujitha Kudaravalli, MD  
**At Noon and 8pm Eastern**

Visit [gi.org/ACGVGR](https://gi.org/ACGVGR) to Register

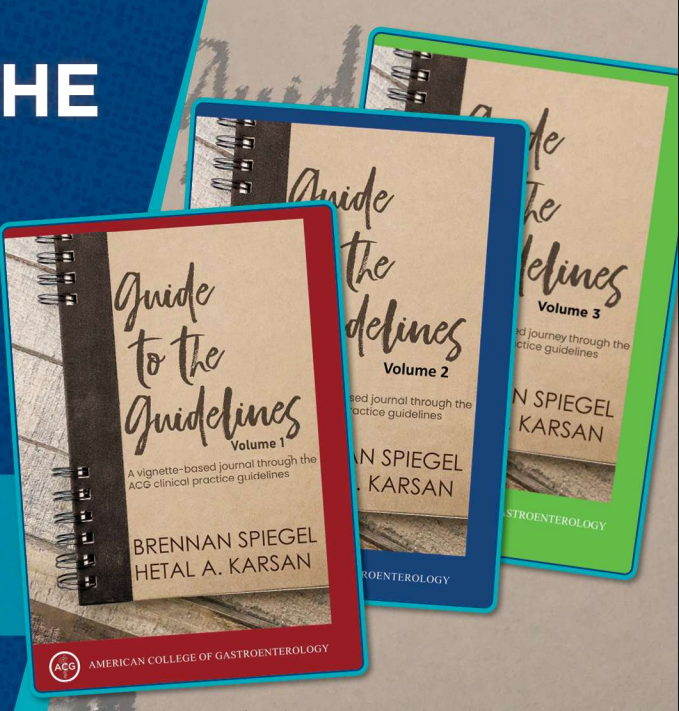
8



# GUIDE TO THE GUIDELINES

*Book Series with New Volume*

Visit <https://members.gi.org/store/> to purchase your copies!



9



Virtual Grand Rounds universe.gi.org

## Disclosures



**Douglas K. Rex, MD, MACG:**  
 Aries Pharmaceutical: Consultant; Boston Scientific: Consultant; Boston Scientific: Grant/Research Support; Braintree Laboratories: Consultant; Erbe: Grant/Research Support; Medtronic: Grant/Research Support; Olympus Corporation: Consultant, Grant/Research Support; Satisfai Corporation: Stockholder; Sebelo Pharmaceuticals: Consultant, Grant/Research Support



**Neha V. Patel, MD, FACG:**  
 No relevant financial relationships with ineligible companies.


\*All of the relevant financial relationships listed for these individuals have been mitigated

10

ACG Virtual Grand Rounds universe.gi.org

# Precision Polypectomy: Mastering Techniques for Safe and Effective Polypectomy

Douglas K. Rex, MD, MACG  
Indiana University School of Medicine  
Indianapolis, Indiana



11

ACG Virtual Grand Rounds universe.gi.org

## Current Approaches to Endoscopic Resection in Colorectum

- All lesions  $\leq$  10 mm in size: Cold snare
- Lesions  $\leq$  3 mm: Cold forceps (large capacity or jumbo) OK
- All SSLs, HPs: Cold EMR or cold snare without injection
- Adenomas 10-20 mm: various approaches
- Adenomas  $\geq$  20 mm: Cold or Hot EMR, ESD for select cases, EMR or ESD plus FTRD

12

ACG Virtual Grand Rounds universe.gi.org

## Two Types of EMR

- Conventional EMR: inject and snare resect
  - Can be done with or without electrocautery
- Underwater EMR: no injection
  - Usually implies electrocautery (at least with larger lesions that will be piecemealed)

13

ACG Virtual Grand Rounds universe.gi.org

## Comments on hot and cold forceps

- Hot forceps
  - No role in resection of small or diminutive polyps
  - Only current role is for hot avulsion of tissue that resists snaring during EMR
- Cold forceps
  - Evidence suggests they're ok for 1-3 mm polyps
  - Should not piecemeal polyps with forceps
  - Often wasted device (if patient has polyps 1-3 mm *and* 4-10 mm)
  - Should be able to remove *all* lesions  $\leq 10$  mm with cold snare

14



## Fundamental questions in endoscopic resection strategy in the colorectum

- Should the lesion be resected *without* or *with* electrocautery?
- Should the lesion be resected en bloc or is piecemeal resection acceptable?
- If en bloc seems preferred what are the resection options?
  - EMR (underwater >> conventional) (up to 20-30 mm)
  - FTRD (up to 15-20 mm)
  - ESD (effective up to any size)

15



## Hot vs Cold Snaring: Fundamental Differences

### Hot snaring

- Cuts deeper through submucosa
- More injury to deep submucosal vessels (delayed bleeding) and thermal injury to the wall (post-coagulation syndrome and delayed perforation)
- More snaring power (can take larger pieces, bulkier pieces)
- Increased costs compared to cold snaring related to closure

### Cold snaring

- Cuts superficially through submucosa
  - Higher risk of recurrence for large ( $\geq 20$  mm conventional adenomas)
- More immediate oozing
- Lower risk of delayed hemorrhage and perforation

16

ACG Virtual Grand Rounds universe.gi.org

## Cold vs Hot Snaring: Appropriate Targets for Use

<p><b>Hot snaring</b></p> <ul style="list-style-type: none"> <li>• Any lesion with a “substantial” risk of cancer (any perceived risk)           <ul style="list-style-type: none"> <li>▪ Bulky (1s) morphology</li> <li>▪ Large thick-stalked pedunculated polyps</li> <li>▪ Lesions with large nodules, depression (2a+2c, 2a+1s)</li> <li>▪ Rectal location</li> </ul> </li> <li>• Any lesion that is difficult to transect without electrocautery           <ul style="list-style-type: none"> <li>• 1s, large 1p</li> </ul> </li> <li>• Any lesion with anticipated fibrosis</li> </ul>	<p><b>Cold Snaring</b></p> <ul style="list-style-type: none"> <li>• Everything <math>\leq</math> 10 mm           <ul style="list-style-type: none"> <li>▪ Including pedunculated</li> </ul> </li> <li>• SSLs of any size           <ul style="list-style-type: none"> <li>▪ SSLs with dysplasia* (ESGE recommends electrocautery for these)</li> </ul> </li> <li>• Flat adenomas (G-LST) 10-19 mm</li> <li>• Flat adenomas (G-LST) <math>&gt;</math> 20 mm**</li> </ul>
--	---

17

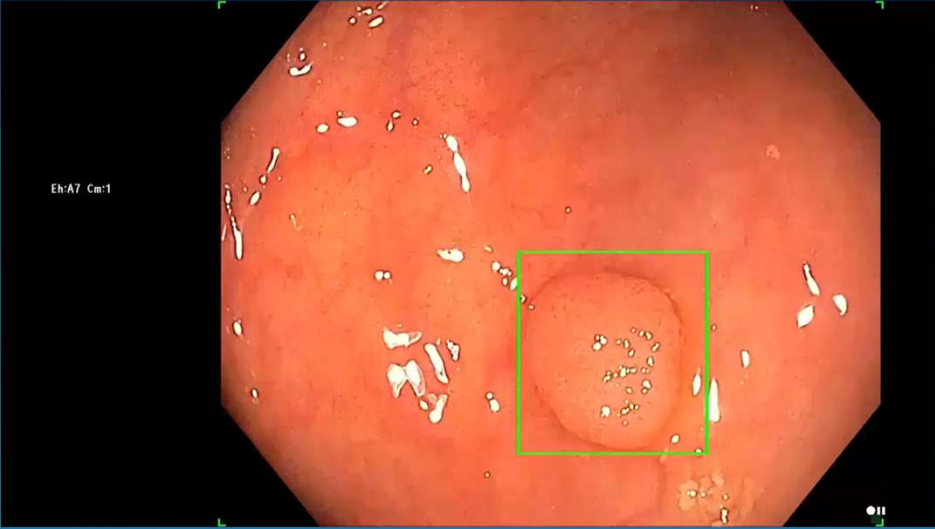
ACG Virtual Grand Rounds universe.gi.org

## When to resect cold

18

ACG Virtual Grand Rounds universe.gi.org

## Polyps $\leq 10$ mm: cold snare



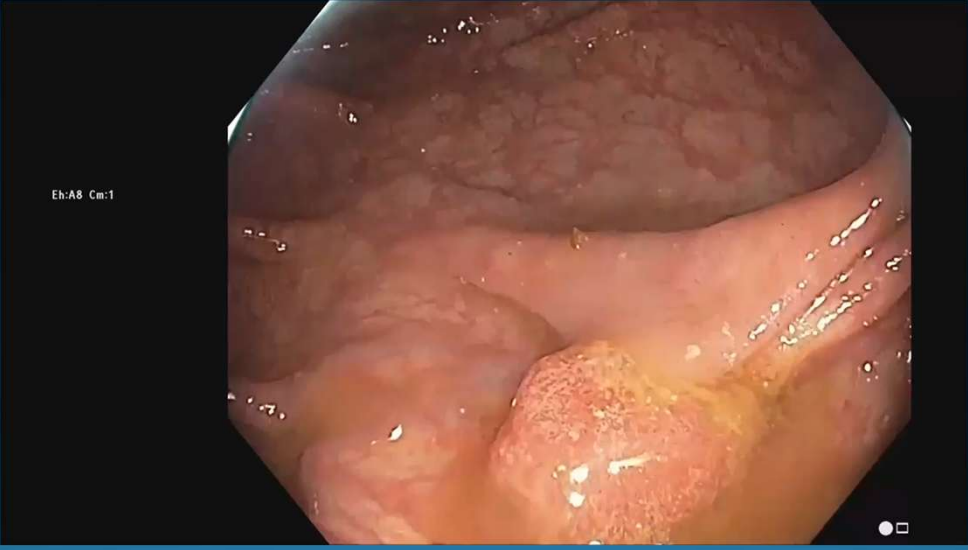
Eh:A7 Cm:1

This endoscopic image shows a flat, polypoid lesion on the colonic mucosa. The lesion is highlighted with a green rectangular box. The surrounding mucosal surface is visible with some mucus and vascular patterns.

19

ACG Virtual Grand Rounds universe.gi.org

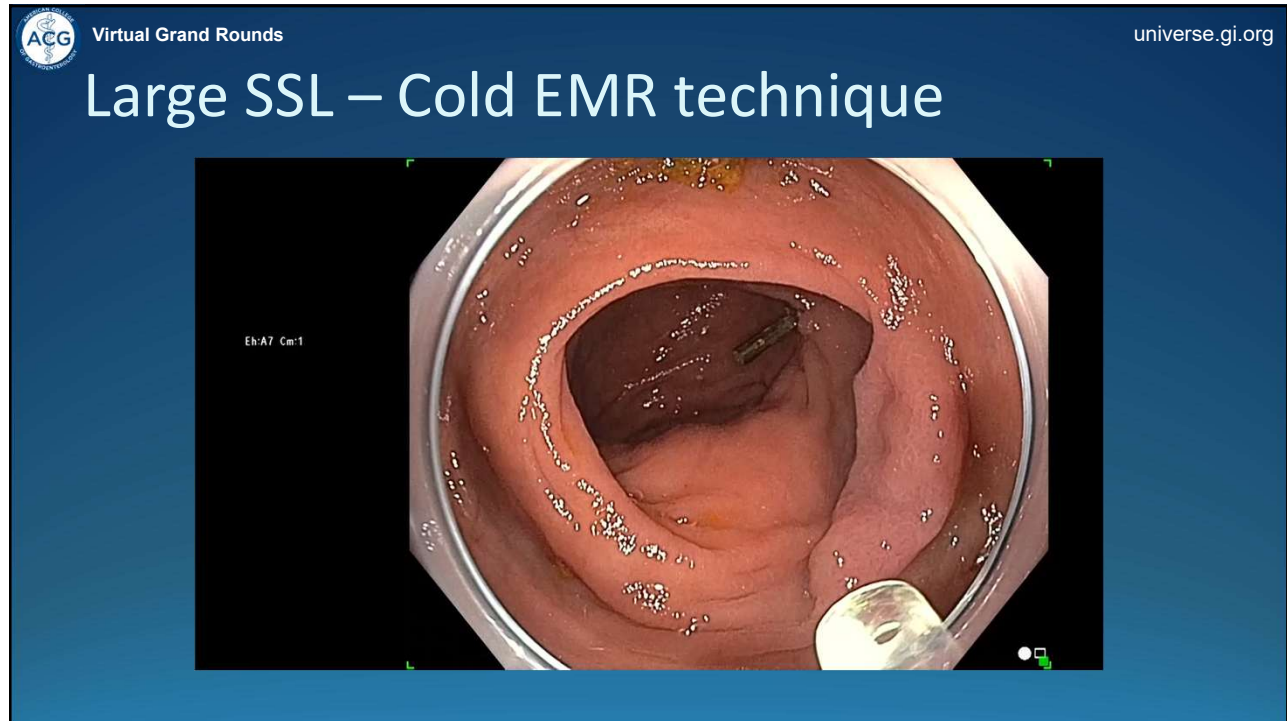
## Pedunculated lesions $\leq 10$ mm: cold snare



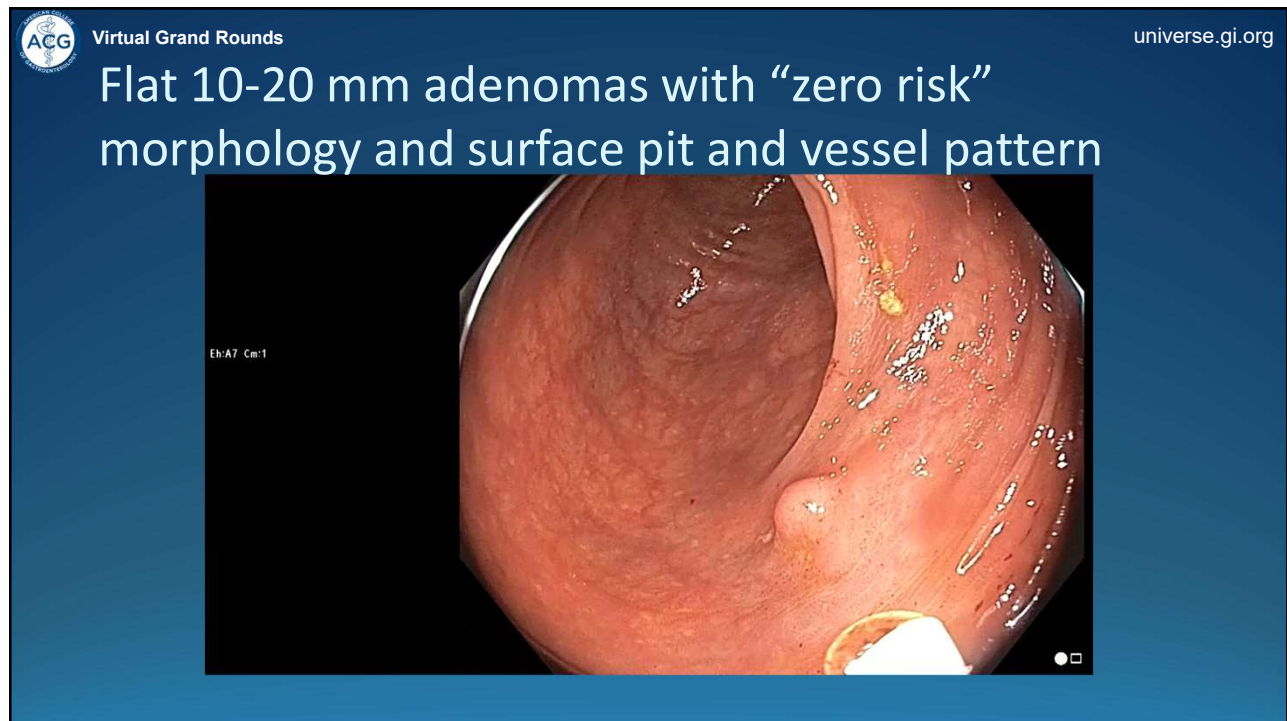Eh:A8 Cm:1

This endoscopic image shows a pedunculated polypoid lesion in the colon. The lesion is clearly attached to the mucosal wall by a stalk (peduncle). The surrounding mucosal surface is visible.

20



21



22

ACG Virtual Grand Rounds universe.gi.org

## Complete resection rate in 6-15 mm polyps

**Study feature**

- 286 lesions 6-15 mm
- 3 U.S. center
- Randomized to cold snare vs hot snare vs cold EMR vs hot EMR
- 4 biopsies from margin and 1 from center
- Overall incomplete resection 2.4%
- Incomplete resection in 10-15 mm 4.6% and 6-9 mm 0%
- Rex et al GIE 2022 doi: 10.1016/j.gie.2022.03.006

**Incomplete resection rates**

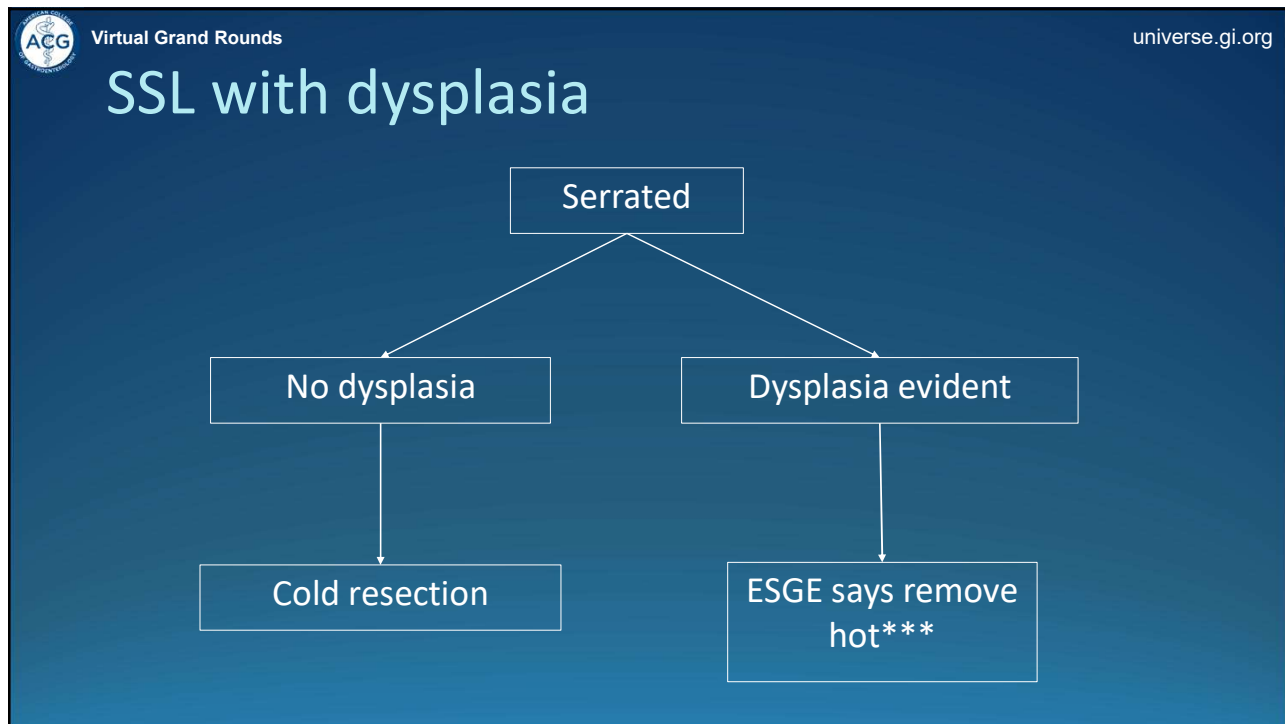
Cold snare	Cold EMR	Hot snare	Hot EMR
0%	1.2%	2.8%	6.2%

23

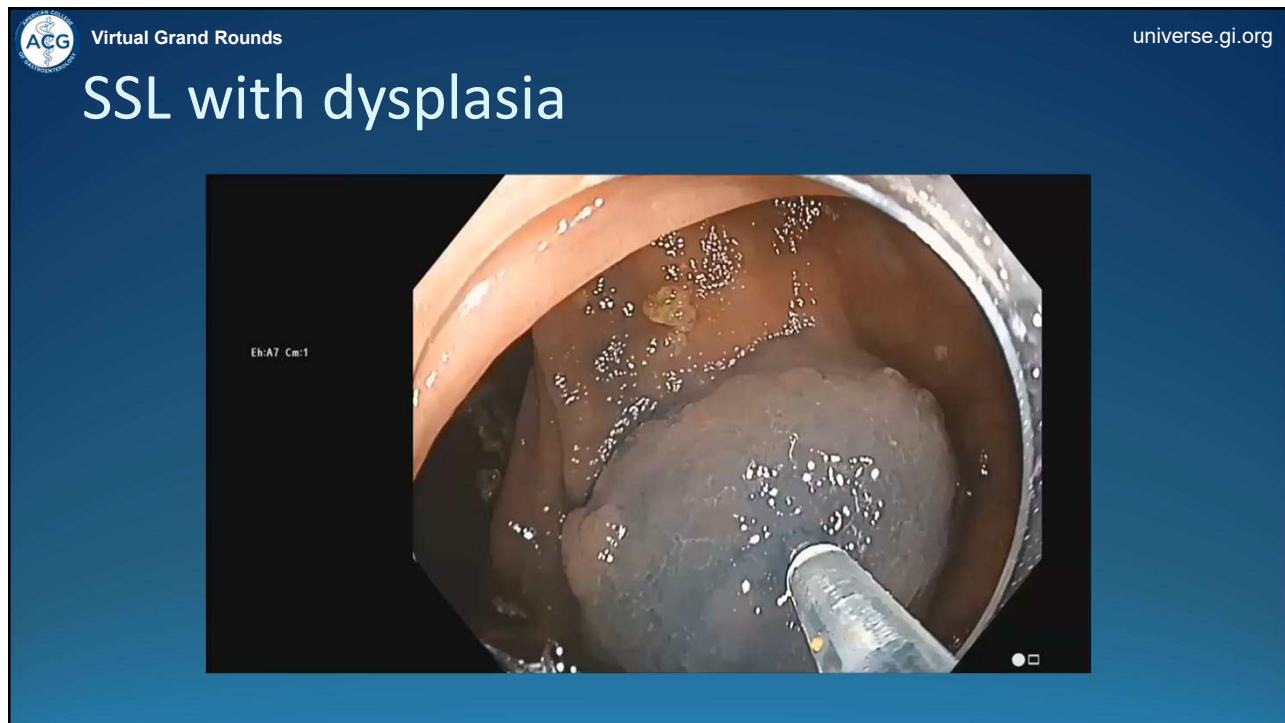ACG Virtual Grand Rounds universe.gi.org

## When to Use Electrocautery

24



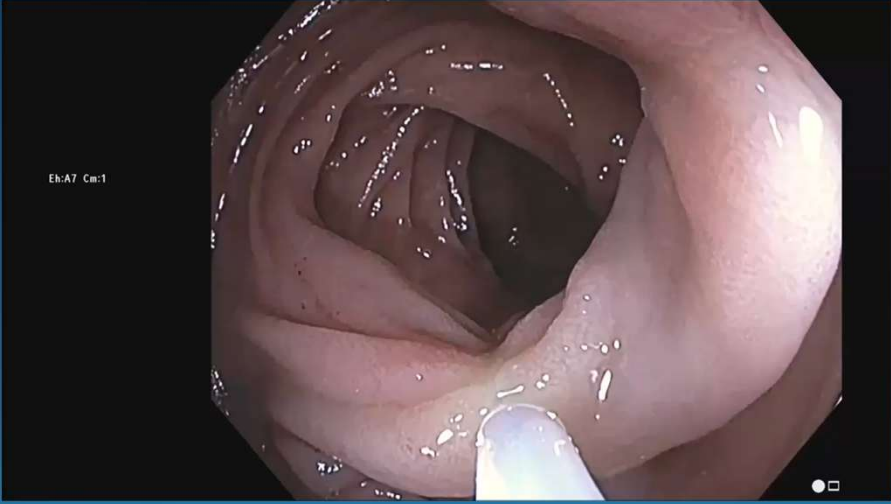
25



26

ACG Virtual Grand Rounds universe.gi.org

## Large pedunculated lesions: electrocautery (forced coag)



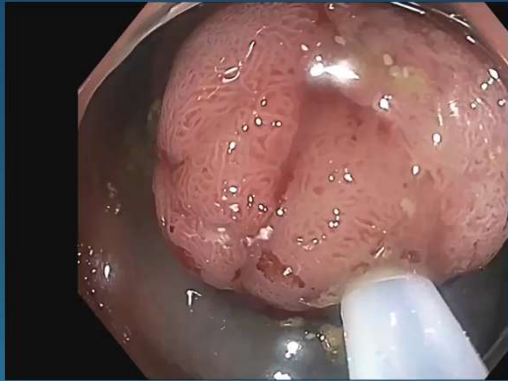
27

ACG Virtual Grand Rounds universe.gi.org

## Bulky (Paris 1s) lesions: electrocautery

### Reasons to use electrocautery

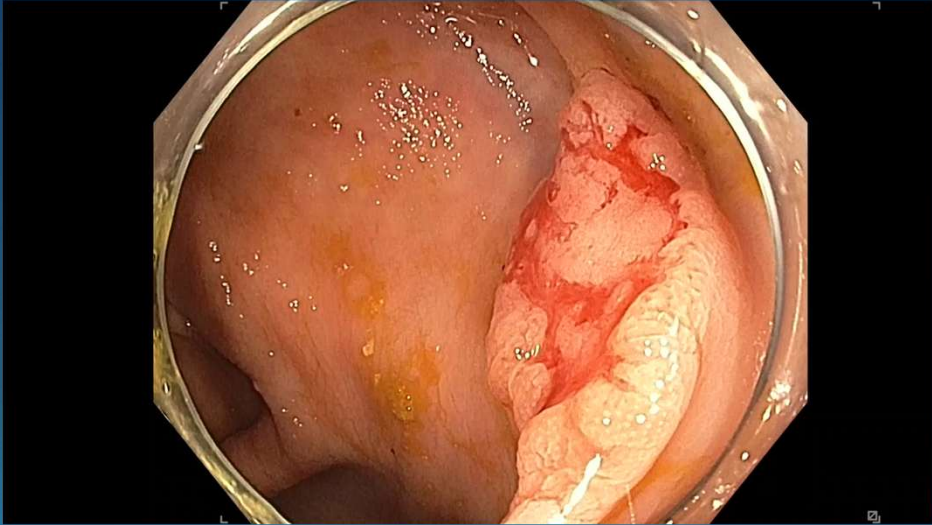
- Hard to cut through cold because of the bulk
- Harder to predict covert cancer in a bulky lesion compared to flat lesion
- Especially important in the rectum
  - The rectum is an independent predictor of cancer



28

ACG Virtual Grand Rounds universe.gi.org

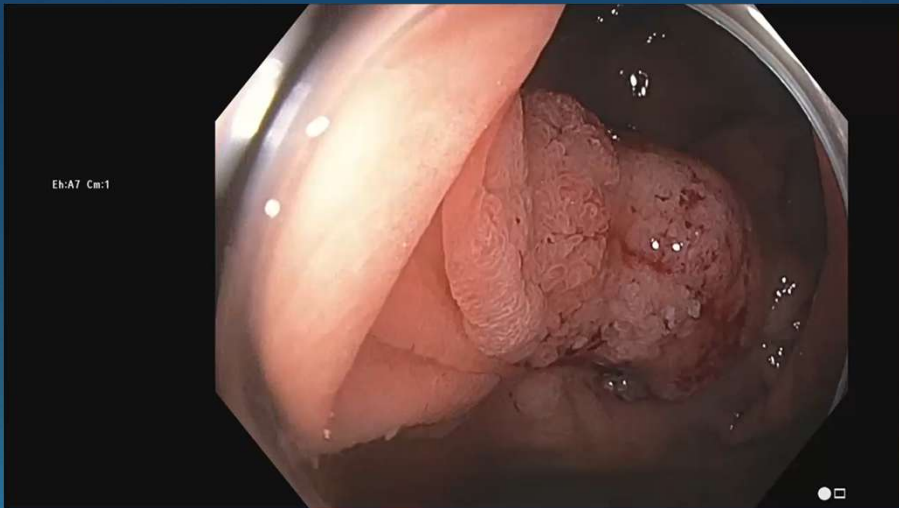
# Bad morphology: electrocautery



29

ACG Virtual Grand Rounds universe.gi.org

# Fibrosis: electrocautery



Eh:A7 Cm:1

30



## Large ( $\geq 20$ mm) non-pedunculated adenomas

- 4 RCTs (3 fully published) have compared hot EMR to cold EMR for this group of lesions
- Meta-analysis of the 4 trials:
  - Sorge et al Endoscopy doi:10.1055/a-2561-5093
- Recurrence rate H-EMR vs C-EMR: 10.8% vs 22.6%
- Delayed bleeding H-EMR vs C-EMR: 3.9% vs 1.2%
- No perforations with C-EMR

31



## Morphology Assessment of LSTs (large adenomas)

- Granular (homogeneous, **mixed nodular**)
  - Less risk of cancer (submucosal invasion)
  - Less submucosal fibrosis
- Non-granular (flat elevated, **pseudodepressed**)
  - higher risk of cancer
  - More submucosal fibrosis

32

ACG Virtual Grand Rounds universe.gi.org

## Morphology of large ( $\geq 20$ mm adenomas) lateral spreading adenomas and cancer risk

33

ACG Virtual Grand Rounds universe.gi.org

## Large non-pedunculated adenomas: candidates for cold piecemeal EMR?

- Granular LST
  - Homogenous G-LST\*\*\*\*\*
  - Mixed G-LST – NO
- Non-granular LST
  - Flat elevated – usually NO
  - Pseudodepressed - NO

34



## Large non-pedunculated adenomas: candidates for cold piecemeal EMR?

- Granular LST
  - Homogenous G-LST\*\*\*\*\*
  - Mixed G-LST – NO
- Non-granular LST
  - Flat elevated – usually NO
  - Pseudodepressed - NO

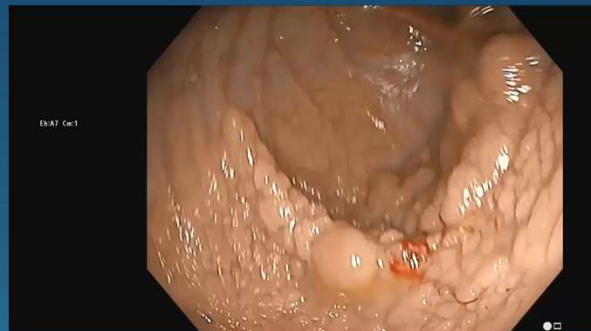35



## Homogenous G-LST: deciding between hot and cold EMR

### Considerations

- Can the defect be closed?
- Can the patient tolerate a complication?
- Can you tolerate a complication?
- Is the patient likely to follow-up?



36

ACG Virtual Grand Rounds universe.gi.org

# Cold EMR on massive homogenous G-LSTs???

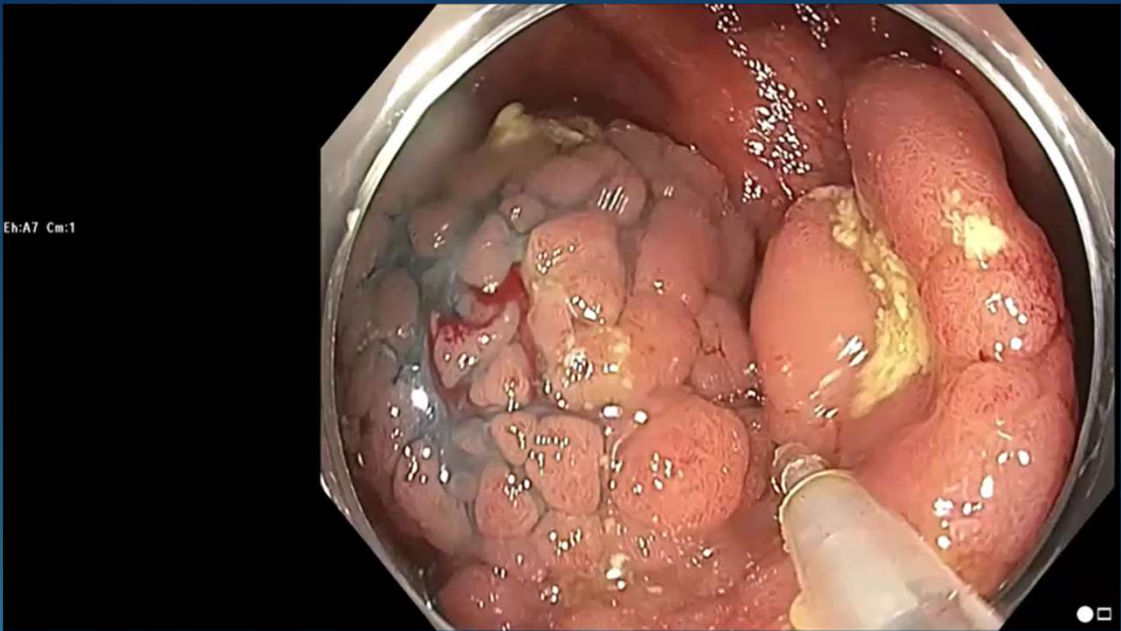


Eh:A7 Cm:1

This endoscopic image shows a large, homogenous, reddish polypoid lesion (G-LST) on the mucosal surface of the colon. The lesion is lobulated and appears to be covered in a thin layer of mucus. The surrounding mucosa is normal in color and texture.

37

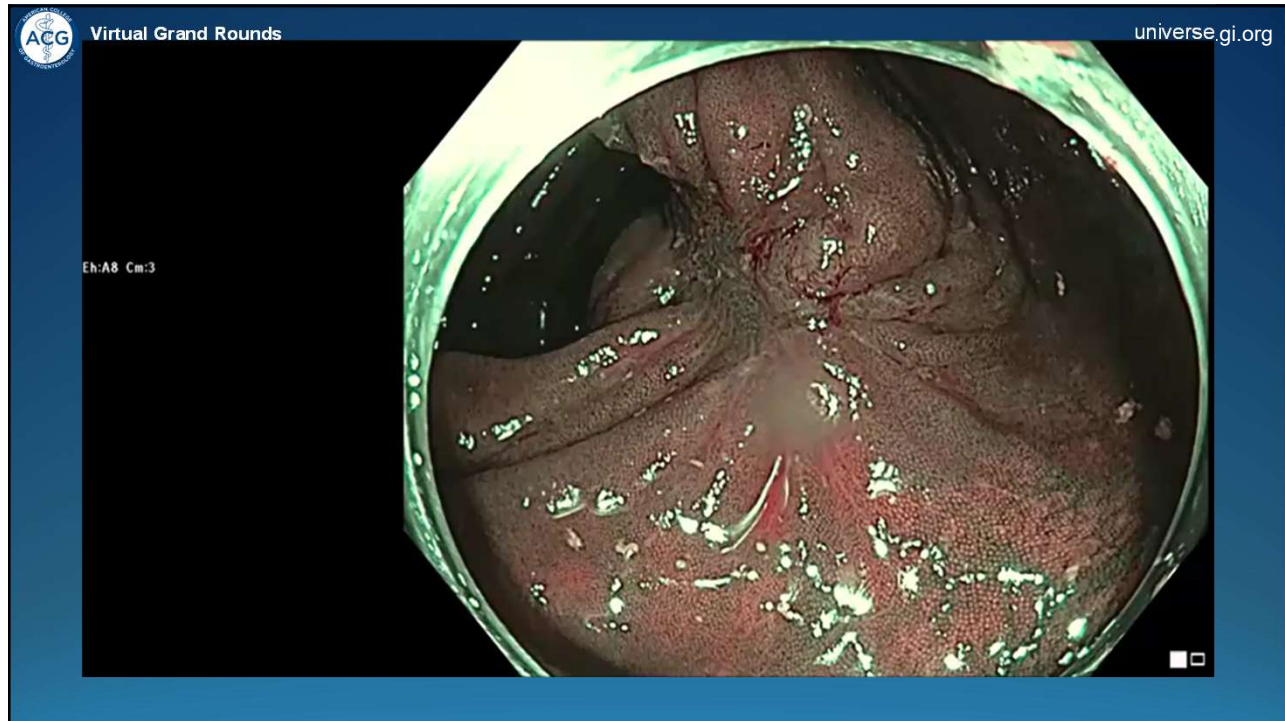
ACG Virtual Grand Rounds universe.gi.org



Eh:A7 Cm:1

This endoscopic image shows multiple large, homogenous, reddish polypoid lesions (G-LSTs) on the mucosal surface of the colon. The lesions are lobulated and appear to be covered in a thin layer of mucus. A biopsy forceps is visible in the lower right corner, indicating that a biopsy is being taken.

38



39

Virtual Grand Rounds universe.gi.org

## Cold vs Hot Snaring: Appropriate Targets for Use

<p><b>Hot snaring</b></p> <ul style="list-style-type: none"> <li>• Any lesion with a “substantial” risk of cancer (any perceived risk)             <ul style="list-style-type: none"> <li>▪ Bulky (1s) morphology</li> <li>▪ Large thick-stalked pedunculated polyps</li> <li>▪ Lesions with large nodules, depression (2a+2c, 2a+1s)</li> <li>▪ Rectal location</li> </ul> </li> <li>• Any lesion that is difficult to transect without electrocautery             <ul style="list-style-type: none"> <li>▪ 1s, large 1p</li> </ul> </li> <li>• Any lesion with anticipated fibrosis</li> </ul>	<p><b>Cold Snaring</b></p> <ul style="list-style-type: none"> <li>• Everything <math>\leq 10</math> mm             <ul style="list-style-type: none"> <li>▪ Including pedunculated</li> </ul> </li> <li>• SSLs of any size             <ul style="list-style-type: none"> <li>▪ SSLs with dysplasia* (ESGE recommends electrocautery for these)</li> </ul> </li> <li>• Flat adenomas (G-LST) 10-19 mm</li> <li>• Flat adenomas (G-LST) <math>&gt; 20</math> mm**</li> </ul>
--	---

40

ACG Virtual Grand Rounds universe.gi.org

## Snare selection

Indication	Rex personal preferences
Cold snaring and cold EMR	<ol style="list-style-type: none"> <li>1. EXACTO (US Endoscopy) or Cap Cold (Boston) or Microtek or Olympus</li> <li>2. Diminutive stiff snare (10mm Boston Captivator 2)</li> </ol>
Hot snaring including EMR	<ol style="list-style-type: none"> <li>1. Stiff snare (e.g. Boston Captivator series or Olympus spiral) – for EMR predominantly 15-20 mm snare size</li> <li>2. Underwater EMR – large snares if going for <i>en bloc</i></li> </ol>
Very large pedunculated lesions	<ol style="list-style-type: none"> <li>1. Large snares with open shape (e.g. Boston 33mm Captivator)</li> </ol>
Cap technique	<ol style="list-style-type: none"> <li>1. 11 mm flexible snare – occasionally 15 mm stiff snare</li> </ol>

41

ACG Virtual Grand Rounds universe.gi.org

## Electrocautery for routine polypectomy (not EMR)

Indication	Cautery settings
Flat and sessile polyps	Forced coag: Effect 2 Max 25 watts <i>or</i> Endocut Effect 3 Cut duration 1 Cut Interval 3
Pedunculated polyps	Coagulation current Effect 2 Max watts 25  <i>or</i> 17-18 watts on fixed output generators

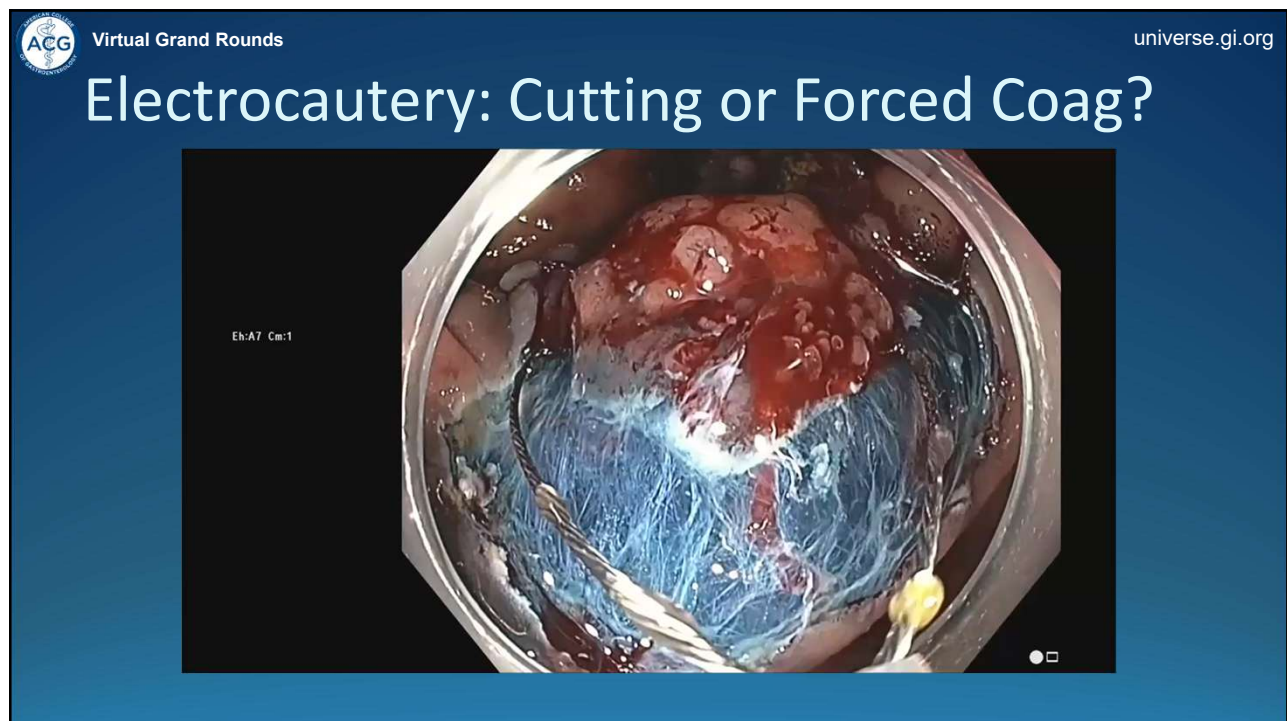
42

ACG Virtual Grand Rounds universe.gi.org

## Electrocautery settings for EMR

Action	Cautery setting
Snaring large EMR pieces	Forced coag Effect 2 Max watts <i>or</i> Endocut Q Effect 2; Cut duration 1, Cut interval 4 (or 3-1-3)
Snare tip coagulation Coag grasper treatment of bleeding	Soft coag Effect 4 or 5; Max watts 80
Hot forceps avulsion	Endocut I Effect 1; Cut duration 4, Cut interval 1
Underwater EMR	Auto Cut Effect 5: Max watts 80 Multiple currents work
Argon plasma coagulation	25-30 watts 0.8-1 liter flow rate

43



44

ACG Virtual Grand Rounds universe.gi.org


## When to use underwater

- To improve chance of en bloc resection for non-pedunculated lesions
- To prevent further thinning of NG-FE
- To float pedunculated lesions in the sigmoid

45

ACG Virtual Grand Rounds universe.gi.org

## En bloc UEMR

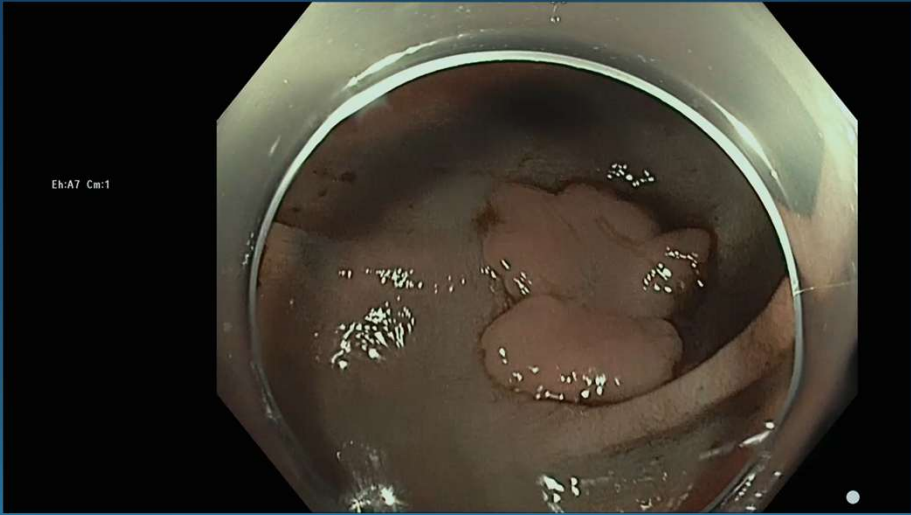


Eh:A8 Cm:1

46

ACG Virtual Grand Rounds universe.gi.org

# Underwater EMR – NG-LST-FE

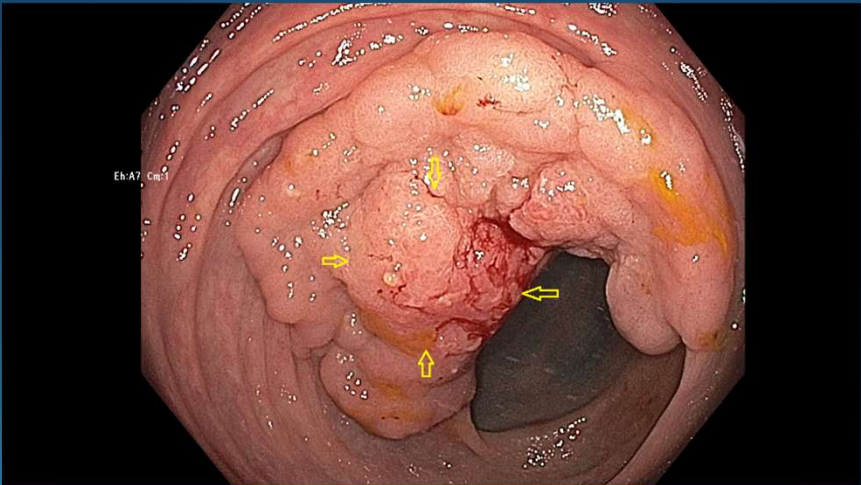


Eh:A7 Cm:1

47

ACG Virtual Grand Rounds universe.gi.org

# ESD: rectal lesions with sessile or granular mixed morphology



Eh:A7 Cm:1

48



## Evaluation Of Quality of Resection

- Effectiveness of Resection Varies 3 fold
  - Pohl et al 2013; 144:74-80
- Competency of Resection Varies 3 fold
  - Duloy et al 2018;87:635-44
- Polypectomy competency does not correlate with ADR
  - Duloy et al 2018;87:635-44

49




## Cold Snare Polypectomy Assessment Tool (CSPAT)

- Put the lesion at 5-6 o'clock\*
- Keep a good working distance\*
- Place the snare accurately (margin of normal tissue)\*
- Retrieve the specimen
- Inspect the site

50

ACG Virtual Grand Rounds universe.gi.org


# Angulated sigmoid: Optimize tip steering (left hand scope grip)



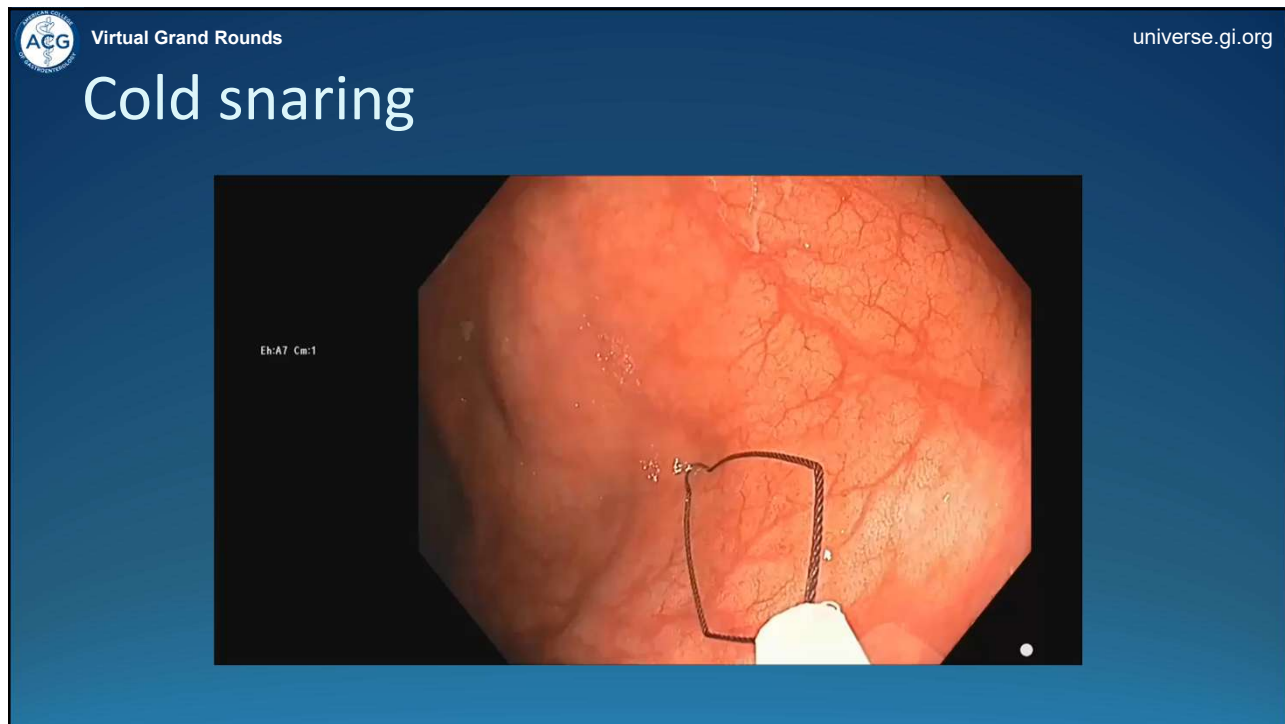
51

ACG Virtual Grand Rounds universe.gi.org

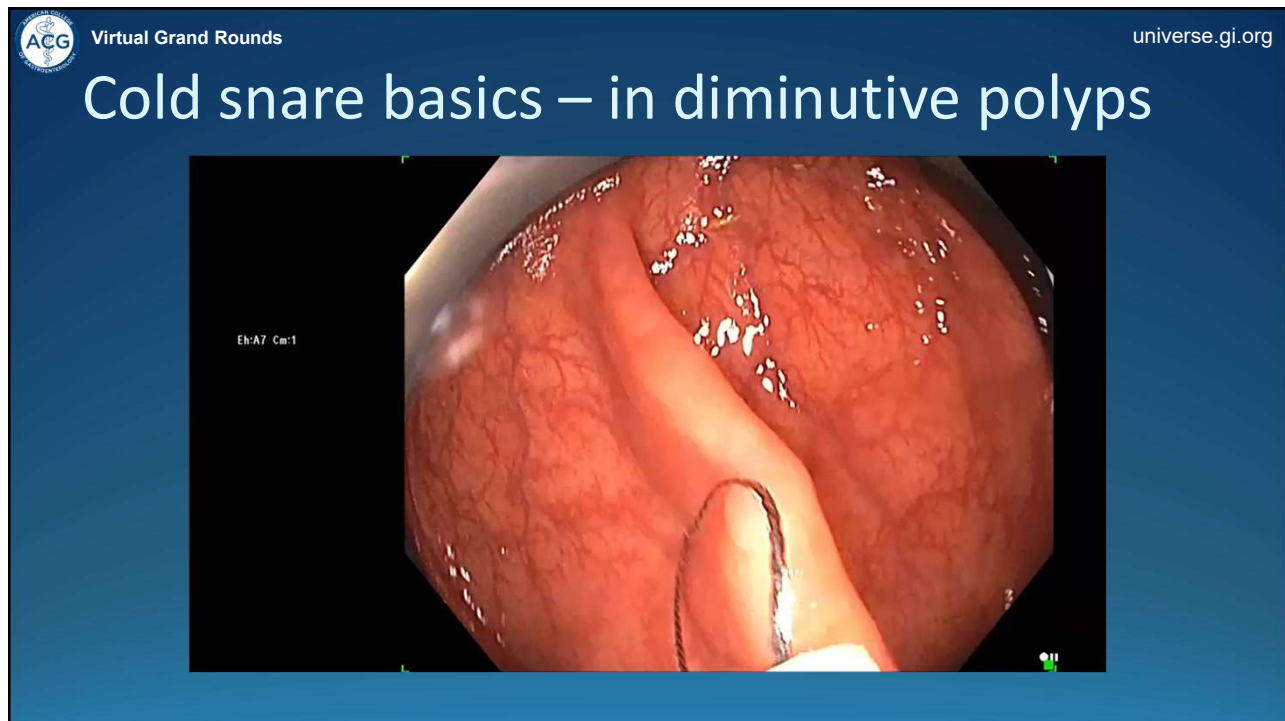
# Angulated sigmoid: Optimize tip steering (left hand scope grip)



52



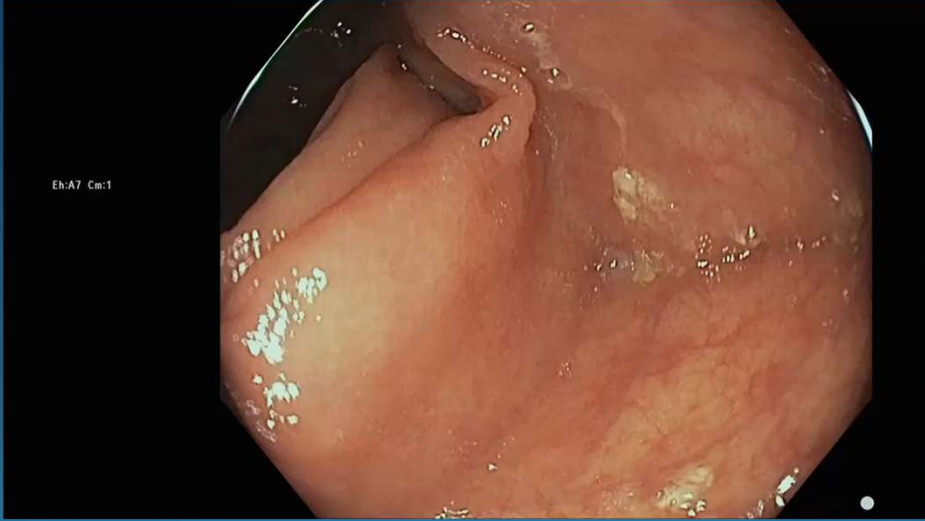
53



54

ACG Virtual Grand Rounds universe.gi.org

## Cold snare 6-10 mm: serrated lesion



Eh:A7 Cm:1

This endoscopic image shows a large, reddish, serrated polypoid lesion in the colon. The lesion has a lobulated, fringed appearance characteristic of serrated polyps. It is being viewed through a colonoscope, with the mucosal folds of the colon visible in the background.

55

ACG Virtual Grand Rounds universe.gi.org

## Extensions of Cold Resection

56

ACG Virtual Grand Rounds universe.gi.org

# Cold Snaring



Eh:A7 Cm:1


This endoscopic image shows a large, sessile polypoid lesion in the colon. A cold snare is positioned around the base of the polyp, ready for resection. The surrounding mucosal folds are visible.

57

ACG Virtual Grand Rounds universe.gi.org

# SSLs – two approaches


### Cold EMR



Eh:A7 Cm:1

This image illustrates the cold EMR technique, where a snare is used to resect a lesion without the use of electrocautery.

### Cold Piecemeal EMR – no injection



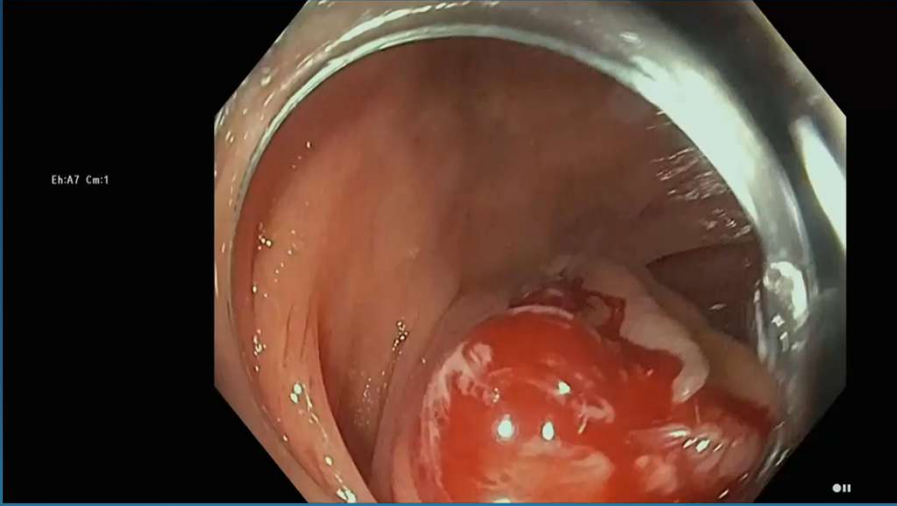
Eh:A7 Cm:1

This image shows a cold piecemeal EMR procedure, where a lesion is removed in multiple small pieces using a snare.

58

ACG Virtual Grand Rounds universe.gi.org

# Large serrated lesion – no injection



Eh:A7 Ca:1

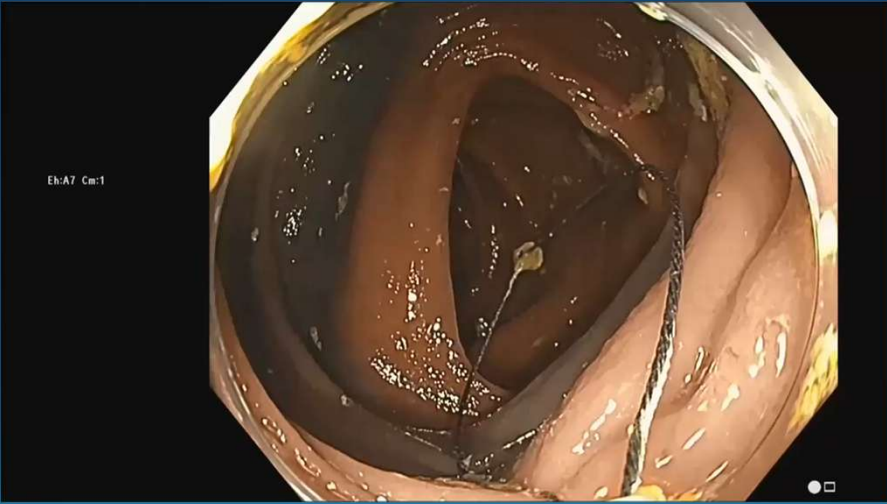
● II

This endoscopic image shows a large, lobulated, red polypoid lesion protruding from the colonic mucosa. The lesion has a serrated appearance and is situated in the lumen of the colon. The surrounding mucosal folds are visible.

59

ACG Virtual Grand Rounds universe.gi.org

# SSLs – Cold EMR in SPS

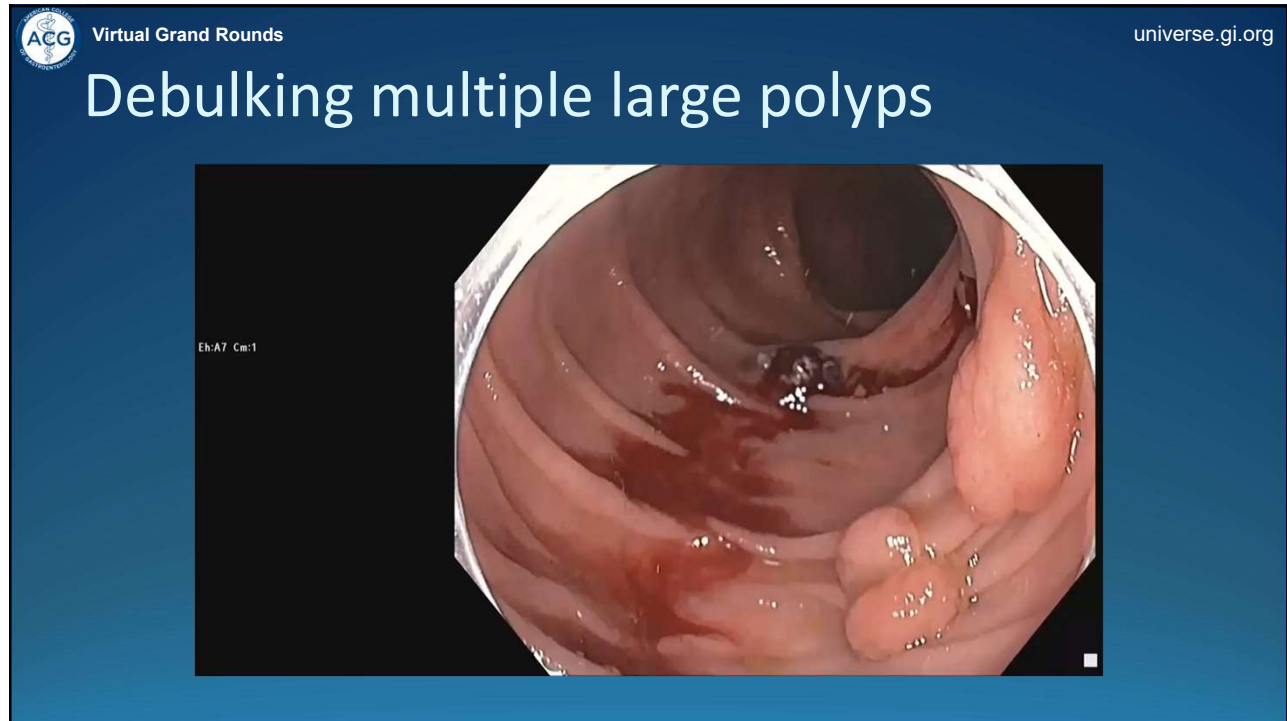


Eh:A7 Ca:1

● □

This endoscopic image shows a serrated lesion being treated with cold EMR. A snare is positioned around the lesion, and a dark, liquid-like substance is visible within the snare, likely representing the resected tissue. The surrounding mucosal folds are visible.

60



61

ACG Virtual Grand Rounds universe.gi.org

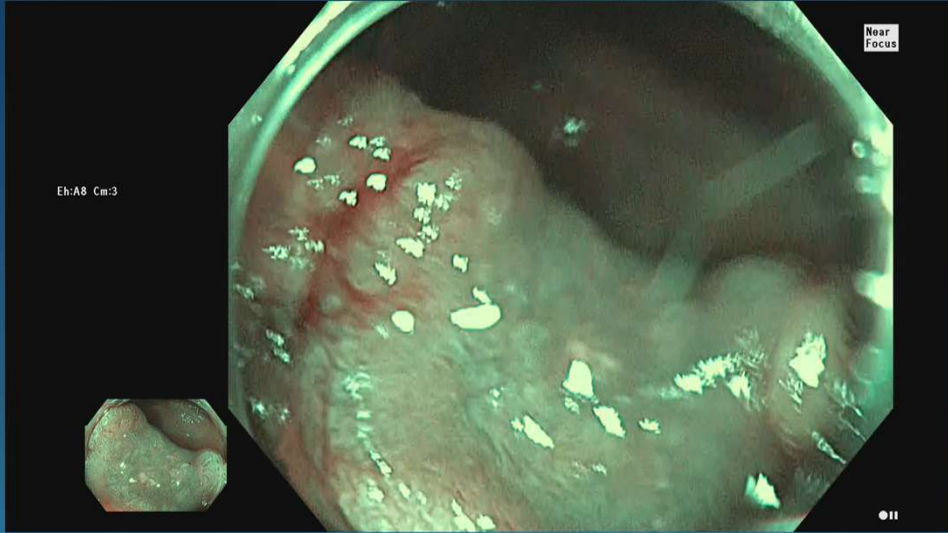
## Hot EMR

Snaring → Avulsion → STSC to Margins

62

ACG Virtual Grand Rounds universe.gi.org

# New Implications of NICE 3/Kudo 5



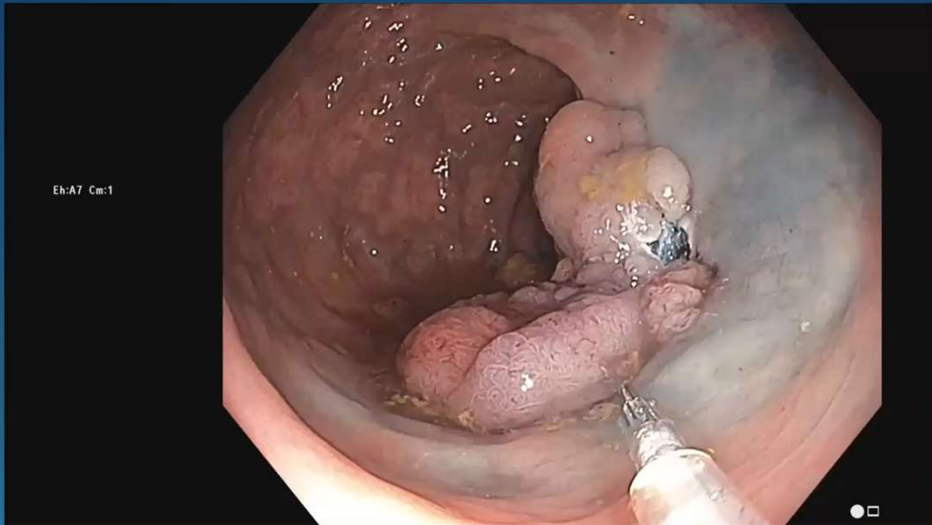
Eh:A8 Cm:3 Near Focus

This endoscopic image shows a mucosal lesion with a lobulated, nodular surface and a reddish hue, characteristic of NICE 3 or Kudo 5. A smaller inset image in the bottom left corner provides a magnified view of the lesion's surface. The text 'Eh:A8 Cm:3' is visible on the left, and 'Near Focus' is in the top right corner of the image frame.

63

ACG Virtual Grand Rounds universe.gi.org

# Dynamic injection



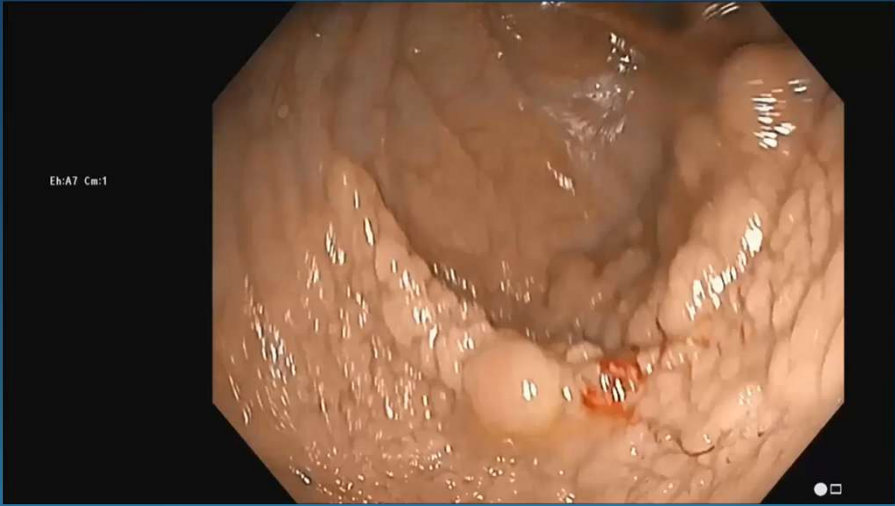
Eh:A7 Cm:1

This endoscopic image shows a mucosal lesion during a dynamic injection procedure. A syringe is visible at the bottom right, injecting fluid into the lesion, which causes it to distend and change shape. The text 'Eh:A7 Cm:1' is visible on the left side of the image frame.

64

ACG Virtual Grand Rounds universe.gi.org

# G-LST cecum



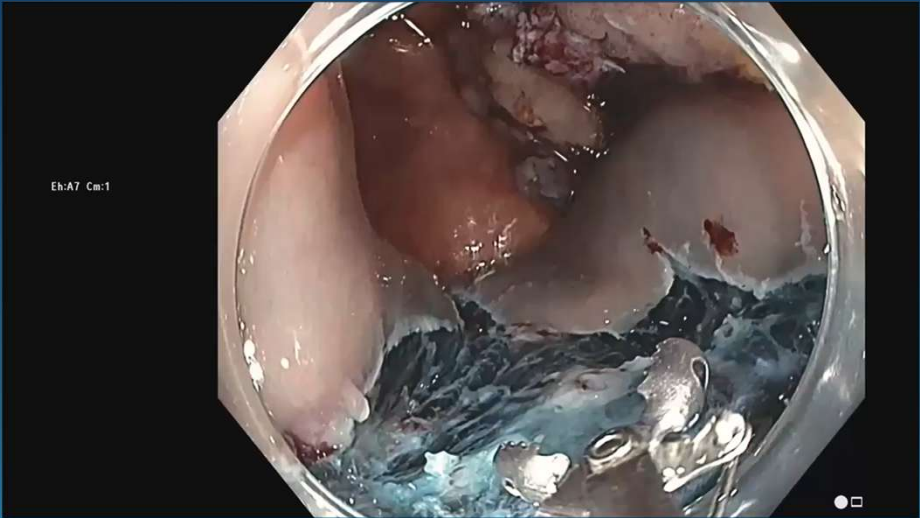
Eh:A7 Cm:1

This endoscopic image shows the interior of the cecum. A large, lobulated, reddish polypoid lesion, characteristic of a Giant Lymphoid Stricture Tumor (G-LST), is visible on the mucosal surface. The surrounding mucosa appears normal. The text "Eh:A7 Cm:1" is visible in the upper left corner of the video frame.

65

ACG Virtual Grand Rounds universe.gi.org

# Snaring → (Avulsion) →



Eh:A7 Cm:1

This endoscopic image shows the snaring and avulsion of a large polypoid lesion. The lesion is being pulled into a snare, and the surrounding mucosa is being cauterized. The text "Eh:A7 Cm:1" is visible in the upper left corner of the video frame.

66

ACG Virtual Grand Rounds universe.gi.org

# Real time STSC margin treatment



Endoscopic view showing a lesion with a blue dye margin. The text "Eh:A7 Cm:1" is visible on the left side of the image. A small white square icon is in the bottom right corner of the image frame.

67

ACG Virtual Grand Rounds universe.gi.org

# Problem Solving

68

ACG Virtual Grand Rounds universe.gi.org

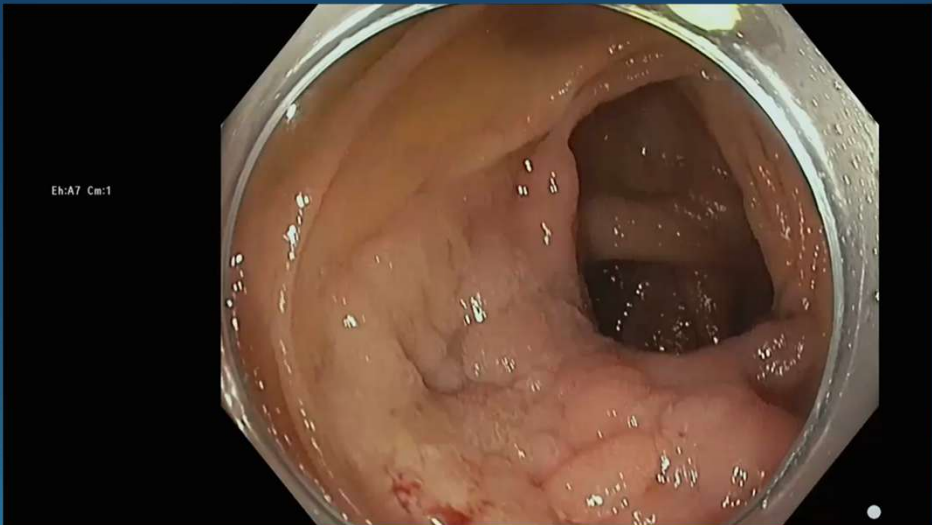
## Problems in Polyp Resection

- Size
- Flat shape
- Access
- Fibrosis
- Numbers of lesions (already discussed – cold resection)

69

ACG Virtual Grand Rounds universe.gi.org

## Size issues, Cap Technique in fibrosis



Eh:A7 Cm:1

70

ACG Virtual Grand Rounds universe.gi.org

# Cap in flat disease



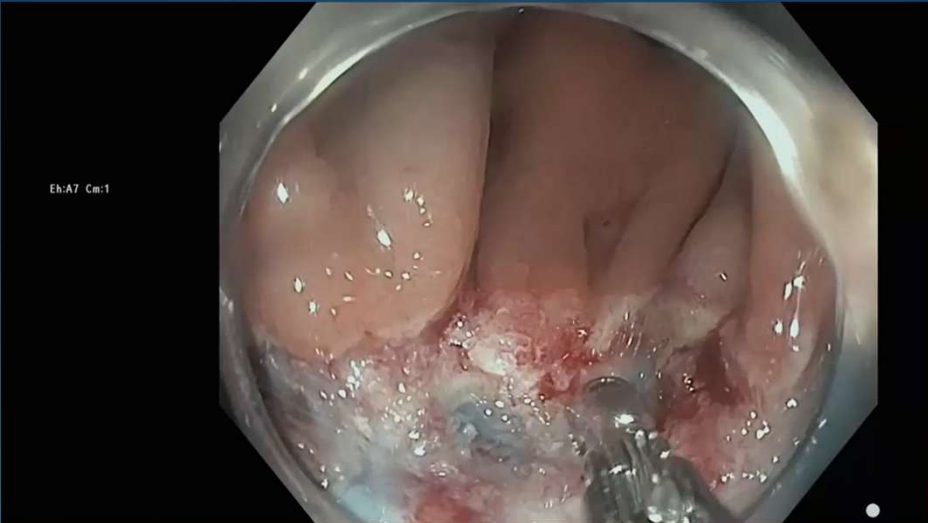
Sex: Age: [redacted]  
D.F.:1  
0/1  
Eh:A1 Cm:1  
Comment:

This endoscopic image shows a flat mucosal lesion in the colon, characterized by a thin, translucent cap. The surrounding mucosa appears normal. The video player interface includes fields for patient sex and age (redacted), a date of February 1st (D.F.:1), a frame count of 0/1, and a time marker of Eh:A1 Cm:1.

71

ACG Virtual Grand Rounds universe.gi.org

# Avulsion in fibrosis



Eh:A7 Cm:1

This endoscopic image shows a mucosal avulsion in a fibrotic area. The mucosal surface is irregular and shows signs of recent trauma or erosion. The video player interface includes a time marker of Eh:A7 Cm:1.

72

ACG Virtual Grand Rounds universe.gi.org

# Water for access and exposure



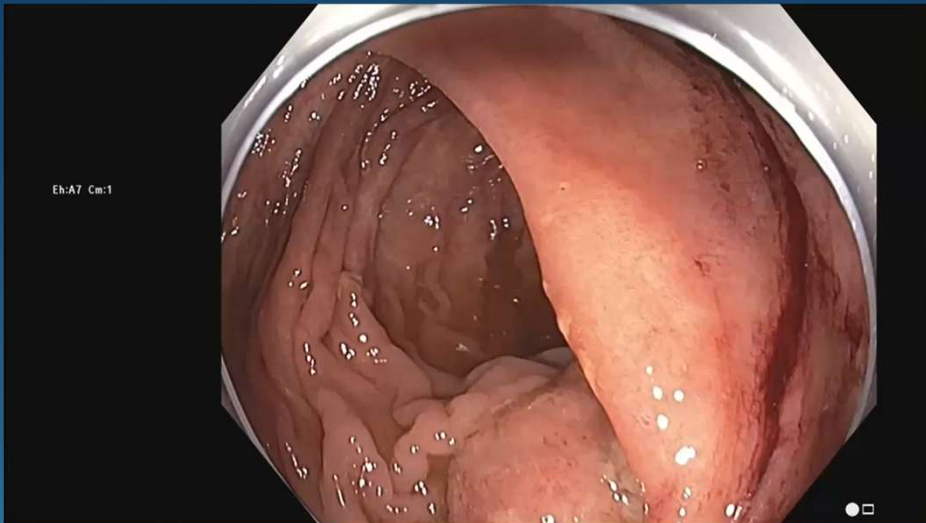
Eh:A7 Cm:1

This endoscopic image shows the mucosal lining of the colon. A thin, clear stream of water is being directed onto the mucosa, creating a glistening surface. The water is used to improve visualization and facilitate the passage of the endoscope. The mucosal folds and vascular patterns are clearly visible under the water spray.

73

ACG Virtual Grand Rounds universe.gi.org

# Water floating on the ICV




Eh:A7 Cm:1

This endoscopic image shows the ileocecal junction. The ileocecal valve (ICV) is visible, and a pool of clear water is floating on its surface. The water is used to provide a clear view of the valve and the surrounding mucosal structures. The mucosal folds and the texture of the ileocecal junction are clearly visible.

74

ACG Virtual Grand Rounds universe.gi.org

# Cap for access and other tricks on ICV



Eh:A8 Cm:1

This slide features a central endoscopic image of the colon. A white, circular cap is visible at the top edge of the frame, partially covering the mucosal surface. The mucosa is reddish-pink and appears moist. The text 'Eh:A8 Cm:1' is overlaid on the left side of the image. The slide has a dark blue background with white text for the title and navigation elements.

75

ACG Virtual Grand Rounds universe.gi.org

# Selected Issues for EMRists

This slide has a dark blue background with the title 'Selected Issues for EMRists' centered in a large, bold, yellow font. The slide includes the ACG logo and 'Virtual Grand Rounds' text in the top left, and the website 'universe.gi.org' in the top right.

76

ACG Virtual Grand Rounds universe.gi.org

# Leave exposed vessels alone



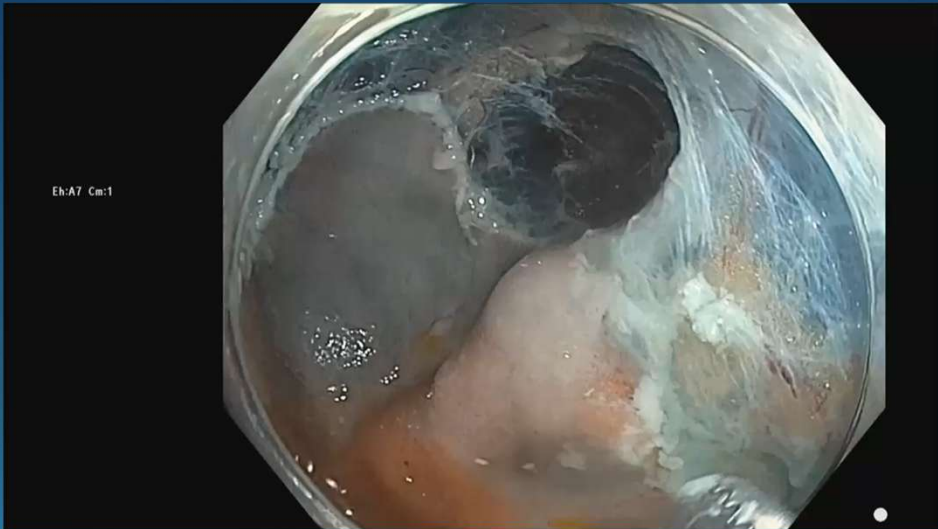
Eh:A7 Cm:1

This endoscopic image shows a mucosal lesion with exposed vessels. The vessels are visible as dark, branching structures. A white handwritten mark '2' is visible on the mucosal surface. The image is framed by a blue border.

77

ACG Virtual Grand Rounds universe.gi.org

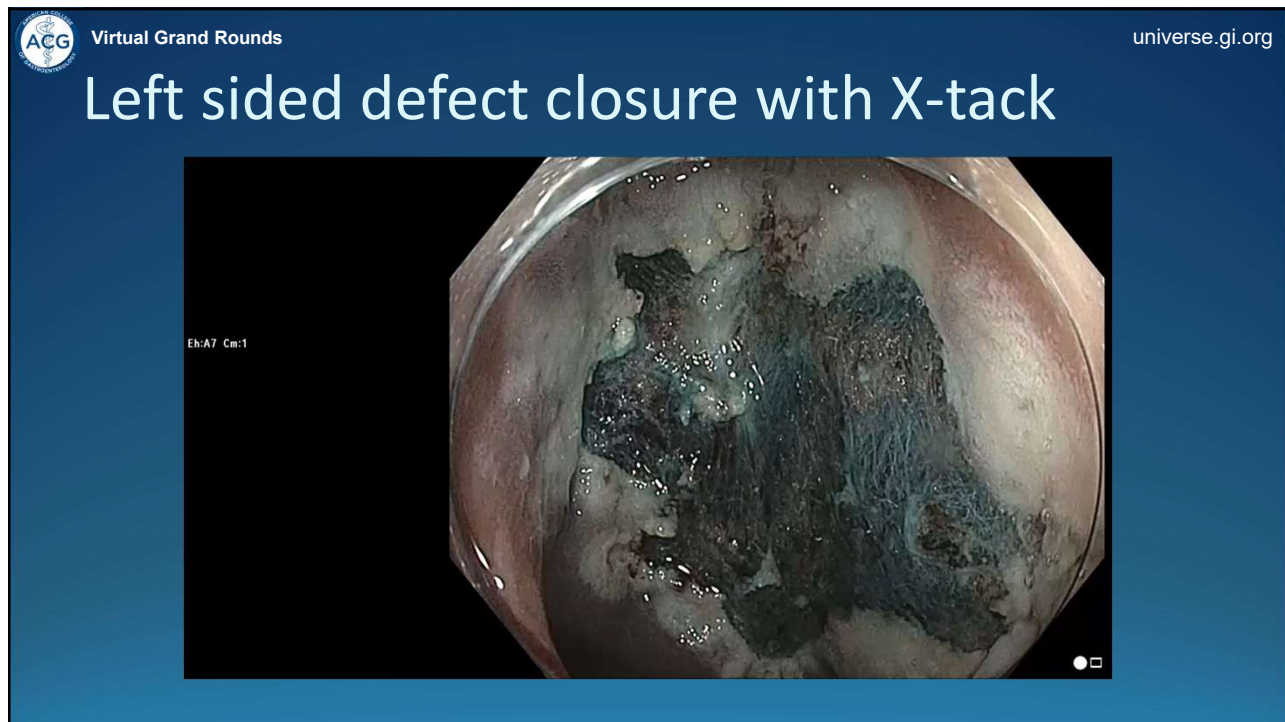# Clip closure: $\geq 20$ mm right colon EMRs



Eh:A7 Cm:1

This endoscopic image shows a mucosal lesion with clip closure. The clip is visible as a dark, circular structure. The mucosal surface is light-colored and appears to be covered in a protective layer. The image is framed by a blue border.

78



79

ACG Virtual Grand Rounds universe.gi.org

## Summary – Tools for Success in EMR

- Serrated – all cold
- Fibrosis – Cap or Avulsion
- Access – Cap and Retroflexion and Underwater
- Debulking and lesions too large to close: Cold
- Underwater: en bloc up to 30 mm, excellent for NG-LST and helps access
- STSC after all hot piecemeal EMRs
- Clip closure: proximal to splenic flexure,  $\geq 20$  mm, hot

80

ACG Virtual Grand Rounds universe.gi.org

## Questions



Douglas K. Rex, MD, MACG



Neha V. Patel, MD, FACG

81

# GI Innovation Through Collaboration

Let's talk... ACG invites you to join the conversation in the GI Circle.

 **ACG's Online Professional Networking Communities**  
Login or sign-up now at: [acg-gi-circle.within3.com](http://acg-gi-circle.within3.com)



**ACG GI Circle**  
Connect and collaborate within GI

82